

Application and Future Perspective of Trichloroacetic acid in the Treatment of Cervical Intraepithelial Neoplasia after Cold Knife Conization

Anita Morarcalieva Chochkova^{1*}, Bashkim Ismaili², Nevenka Velickova³,
Blaze Chochkov¹, Marina Nakova¹

¹ Department of Obstetrics and Gynecology, PHI General Hospital- Gevgelija, N. Macedonia

² Department of Operative Gynecology, SHOG Mother Theresa Chair- Skopje, N. Macedonia

³ Faculty of Medical Science, University Goce Delcev- Stip, N. Macedonia

Abstract

Background: Factors that contribute to development of cervical intraepithelial neoplasia are: age older than 55, and infection with persistent, high risk Human papillomavirus (HPV). If the HPV remains in an episomal nonintegrated state, it results with low grade lesion and if virus becomes integrated into the human genome, high grade lesions and cancer may develop. Low grade lesion is cervical intraepithelial neoplasia and it refers to mildly atypical cellular changes in the lower third of the epithelium. High grade cervical lesions are cervical intraepithelial neoplasia II and III. CIN II refers to moderately atypical cellular changes confined at the basal two thirds of the epithelium and CIN III refers to severely atypical cellular

changes encompassing greater than two thirds of the epithelial thickness. Cold knife conization usually is the treatment of choice for high grade cervical lesions.

Case report: We present a case of new creative treatment with 85% trichloroacetic acid, of low grade cervical intraepithelial neoplasia, which was a residual cervical lesion after a cold knife conization preformed for high grade cervical intraepithelial neoplasia grade treatment.

Conclusion: Single topical use of 85% trichloroacetic acid is an effective treatment for residual persistent cervical intraepithelial neoplasia of low grade, after cold knife conization and provides long term remission and satisfying Human papillomavirus clearance. Thus

85% trichloroacetic acid treatment can directly diminish morbidity and mortality of Human papilloma virus related to precancerous cervical lesions and cervical carcinoma.

Keywords: HPV, cervical intraepithelial neoplasia, cervical cancer, trichloroacetic acid, conization, colposcopy

INTRODUCTION

Cervical cancer is considered the third most common cancer in women worldwide. There are 604 237 new diagnosed cases, representing 6.5% of all female cancers and 341 843 deaths in 2020, 90% of whom were in less developed countries. Incidences of cervical cancer are disproportionately distributed between developed and less developed countries. Developed countries have progressively declined the incidence of cervical cancer by providing cancer screening programs and HPV vaccination programs. According to Global Cancer Observatory, our country, North Macedonia is among the countries with middle high age standardized rate of 7,5 (1). Statistical review of Institute of Public Health of North Macedonia showed that in average there are 150 new diagnosed cases of cervical cancer per year in our country, and one third of them died (2). One of the main factors that contribute to the development of cervical dysplasia is the age, particularly women older than 55, as 50% of high risk Human Papilloma Virus (HPV) infections persist in women older than 55. Duration of infection is well known as predisposing factor for appearance of cervical precancerous lesion. And high oncogenic HPV DNA types are more related to cervical lesions. If the HPV remains in an episomal nonintegrated state, it results with low grade lesion and if virus becomes integrated into the human genome, high grade lesions and cancer may develop (3). Low grade lesion is cervical intraepithelial neoplasia1 (CIN I) and it refers to

mildly atypical cellular changes in the lower third of the epithelium. High grade cervical lesions are cervical intraepithelial neoplasia 2 (CIN II) and 3 (CIN III). CIN II refers to moderately atypical cellular changes confined at the basal two thirds of the epithelium and CIN III refers to severely atypical cellular changes encompassing more than two thirds of the epithelial thickness. If the lesion breaks through the basal membrane, then microinvasive carcinoma is diagnosed (4).

CASE REPORT

A 41 years old woman comes at the Obstetrics and Gynecology department (PHI General Hospital Gevgelija) for a regular checkup. She has regular menstrual cycle and the last menstruation ceased two days ago. The ultrasound examination showed finding according to the patients age, without visible pathological changes. The vaginal examination showed hypertrophic uterine cervix with large transformational zone (TZ) and a few ovulae Nabothie. Papanikolaou (PAP) smear was taken for evaluation, and the test results revealed atypical squamous cells of undetermined significance (ASC-US), according to The Bethesda system (TBS), 2014. DNA Real Time Polymerase Chain Reaction (HPV DNA RT PCR) assay confirmed presence of high risk HPV type 33 with clinical significance. The colposcopy, according to The International Federation of Cervical Pathology and Colposcopy nomenclature 2011 (2011 IFCP nomenclature), was adequate with completely

visible squamocolumnar junction (SCJ) and type 1 TZ. Ectopy was absent and the lesion was inside the TZ taking 2 quadrants and approximately 25% of the uterine cervix. The acetowhite epithelium was with irregular border, thin, milky and there was fine mosaic present. Vessels of the uterine cervix were fine and regular, stained distinctly yellow with Lugol's iodine. This colposcopy finding was rated with Swedescor 5, which indicates low grade squamous intraepithelial lesion (LSIL). Endocervical curettage was done in the same time with biopsy. Histopathology analysis showed CIN II. We decided to preform classical diagnostic cold knife conisation, but the patient's wish was to obtain a cone not higher than 1cm, because of her wish for another pregnancy and spontaneous delivery at term. The diagnosis of CIN II was confirmed histopathologically, but the margins of the cone were not in healthy tissue. They passed through CIN I zone. The patient was controlled in the next year with PAP smears in four months intervals, that showed persistent CIN I. We decided to preform noninvasive cervical peeling with 85% trichloroacetic acid (TCA). A small cotton swab was saturated with TCA and applied to the ectocervix. A thin layer was applied to the ectocervix and TZ and allowed to turn white, indicating precipitation of the proteins. TCA has low viscosity, therefore care was taken because it can easily drip down onto normal tissue, which can also become chemically coagulated. To treat the caudal part of the cervical canal the wooden stick end of the cotton swab was dipped into

trichloroacetic acid and when saturated, it was applied in the cervical canal. Two, four and twelve months after the procedure, PAP smears showed normal findings and the HPV DNA RT PCR assay, one year after the procedure showed presence of minimal amount of HPV DNA type 33 without clinical significance.

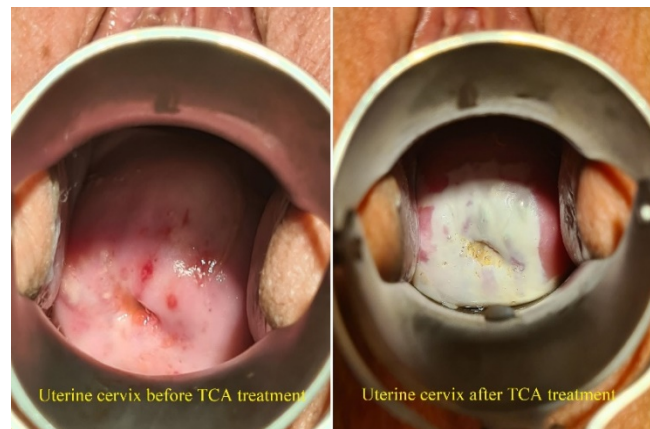


Figure 1. Uterine cervix before and immediately after the treatment with trichloroacetic acid

DISCUSSION

Cervical cancer remains a large burden for women's health globally. Screening programs of greater coverage, vaccination of the female and male population and new effective treatments of subclinical HPV infections of the uterine cervix and cervical intraepithelial neoplasia scan, contribute to decline the morbidity and mortality rate of cervical carcinoma, especially in women in reproductive age. Rajalingam et al. (2009), proved that TCA causes protein denaturation (5). According to this, the infected epithelium denudes and peels off and provides epithelization of the basal membrane with new healthy cells. In the study of Geisler et al. 2016, the efficacy of TCA after a single topical application was

established, with no major differences between high grade and low grade CIN and with remission rates of 80,3% and 82,3% respectively (6). Based on the Suwartono and Andrijono's (2020) study, there is no significant difference between application of 85% TCA compared with cryotherapy for treatment of patients with positive visual inspection with acetic acid (VIA) result. So the TCA treatment should be favored unlike the cryotherapy, which represents an invasive technique requiring special professional and logistic support (7). The ongoing prospective study, TRICIN, which is sponsored by Krankenhaus Barmherzige Schwestern Linz and was planned to end in December 2022, expects high remission and regression rates after single topical use of 85% TCA for CIN I and II, of 70% or even higher (8). Our case report demonstrated that with a lot of knowledge and patience, the patient's wishes can be taken into account and at the same time to respect the conventional protocols for diagnosis and treatment of high grade cervical lesions, adding a new creative way of achieving remission of the residual cervical lesion. By chemical coagulation of proteins, after a single treatment of topical TCA for CIN I and HPV infection, as a residual lesion after a diagnostic cold knife conization, we got major feedback and high HPV clearance. This treatment should be favored because the acid is cheap, the technique does not require special training to perform, anesthesia is not needed because the treatment causes little or no pain at all. Moreover, it can be performed outpatient without

hospitalization and the patient can be discharged home immediately after the treatment, advised not to have sexual intercourses for two weeks, to take showers instead of a bath and to use sanitary towels instead of tampons.

CONCLUSION

Single topical use of 85% TCA is an effective treatment for residual persistent CIN I, after cold knife conization and provides long term remission and satisfying HPV clearance. Thus, 85% TCA treatment can directly diminish morbidity and mortality of HPV related precancerous cervical lesions and cervical carcinoma.

Acknowledgements: None declared.

Conflict of Interest Statement: The authors declare that they have no conflict of interest.

REFERENCES

1. Sung H, Ferlay J, Siegel RL, Laversanne M, Soerjomataram I, Jemal A, Bray F (2021). Global Cancer Statistics 2020: GLOBOCAN Estimates of Incidence and Mortality Worldwide for 36 Cancers in 185 Countries. *CA Cancer J Clin* 71(3):209-249. doi: 10.3322/caac.21660.
2. Речица В, Тахири Ј (2020). Рак во Република Северна Македонија 2010-2019.
3. Pinidis P (2016). Human papilloma virus' life cycle and carcinogenesis. *Maedica* 11(1):48-54. PMID: 28465751.

4. DiSaia PJ, Creasman WT (2011). *Clinical Gynecologic Oncology*, 7th edition, Elsevier Inc.
5. Rajalingam D, Loftis C, Xu JJ, Kumar TKS (2009). Trichloroacetic acid induced protein precipitation involves the reversible association of a stable partially structured intermediate. *Protein science* 18(5):980-93.
<https://doi.org/10.1002/pro.108>.
6. Geisler S, Speiser S, Speiser L, Heinze G, Rosenthal A, and Speiser P. Short-Term Efficacy of Trichloroacetic Acid in the Treatment of Cervical Intraepithelial Neoplasia. 2016; 127(2):1.
DOI:10.1097/AOG.0000000000001244.
7. Suwartono H, Andrijono. Efficacy of Trichloroacetic acid (TCA) compared to cryotherapy in treating patients with positive VIA result. *INAJOG* 2020.
doi.org/10.32771/inajog.v8i4.1382.
8. TRICIN: Prospective study on the efficacy of single topical trichloroacetic acid (TCA) 85% in the treatment of cervical intraepithelial neoplasia (CIN 1/2) 2020. Clinical NCT04400578.