

WEBINO with Vertical Gaze Palsy - A Rare Syndrome Revisited

Anubhav Chauhan¹, Kalpana Sharma²

¹Department of Ophthalmology, Dr Yashwant Singh Parmar Govt. Medical College,
Nahan, District Sirmour, Himachal Pradesh, India

²Department of Ophthalmology, Indira Gandhi Medical College, Shimla, Himachal Pradesh, India

Abstract

A 45 years old male presented to us with a history of sudden onset painless diplopia for the past two weeks. There was a previous history of cerebrovascular accident (CVA) three weeks back. Examination revealed bilateral internuclear ophthalmoplegia with vertical gaze anomaly and postural instability. A diagnosis of wall eyed bilateral

internuclear ophthalmoplegia (WEBINO) with probable progressive supranuclear palsy (PSP) was made. This is a very rare disorder; the ocular symptoms developing one week after a CVA plus PSP like signs and symptoms makes it a rarest of rare case.

Keywords: ocular, brain, syndrome

CASE REPORT

A 45 year old male (Figure 1) accompanied by his relatives presented to the department of ophthalmology with a history of sudden onset of double vision for the past two weeks with progressive worsening of symptoms. There was no other complaint. There was also a history of developing sudden onset weakness on the right side of body (right upper and lower limbs) three weeks earlier for which he was already on treatment from some medical specialist. Treatment records brought by him revealed that he suffered a cerebrovascular accident three weeks before and was on treatment with aspirin, ramipril and atorvastatin. The computerized tomography report showed an acute infarction involving the vermis on the left side and posterior part of pons. His blood reports in the form of a complete blood count, blood sugar, liver and renal function tests, lipid profile and homocysteine levels were within normal limits. There was no other significant medical, surgical, personal, family or drug abuse history nor previous history of ocular disease or trauma. The patient was non smoker, non alcoholic and vegetarian.

His visual acuity was 6/24 in both the eyes without any improvement; pupillary reactions, intraocular pressure, fundus examination and B Scan ultrasonography were normal. Perimetry could not be performed. Torch light examination revealed the ocular motility anomaly in the form of primary gaze exotropia with bilateral adduction impairment and nystagmus of the

abducting eye. Bilateral vertical eye movements were severely limited and convergence was absent. His general physical and systemic examination was carried out and the positive findings were postural instability and decreased power of the right upper and lower limbs with up going plantar reflex bilaterally. Based on the above findings, a diagnosis of WEBINO with probable PSP (according to the diagnostic criteria) was made (1). The patient was admitted in the eye ward and a plan of management was discussed which included a brain magnetic resonance imaging, neurologist consultation and prismatic correction for diplopia. But the patient left without medical advice and was lost for treatment and follow-up.

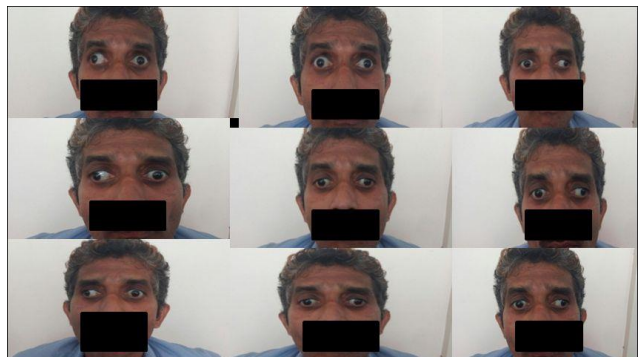


Figure 1. All 9 positions of gaze

DISCUSSION

WEBINO is a rarely reported syndrome named by Lubow in 1971 (2). It is caused by lesions in the medial longitudinal fasciculus (MLF), and is classically characterized by paresis of adduction on lateral gaze associated with nystagmus on abduction of the contralateral eye (3). The most

common causes of WEBINO are demyelination and stroke (4), while other causes are toxic, infectious, degenerative, traumatic, postsurgical, and neoplastic conditions (5). Association with Devic's disease has also been reported (6).

The other features of WEBINO include vertical gaze palsy, up-beat nystagmus and is again thought to be due to bilateral MLF damage along with abnormalities of the medial rectus sub nuclei of the ventral oculomotor nuclear complex leading to bilateral exotropia and bilateral convergence failure. Vertical gaze abnormalities in WEBINO is also due to involvement of the interstitial nucleus of Cajal in the midbrain-thalamic region (7).

WEBINO should be differentiated from the exotropia of one and a half syndrome which denotes unilateral horizontal gaze palsy and internuclear ophthalmoplegia and occurs in the pontine lesion involving the paramedian pontine reticular formation and MLF (8).

The prognosis of WEBINO has not been well documented. Management includes treating the underlying conditions and if any post treatment diplopia persists, surgery and botulinum toxin injections are used. Alternative management options include the use of prisms and occlusion therapy (9).

Acknowledgments: We would like to thank our patient.

REFERENCES

1. Rehman HU. Progressive supranuclear palsy. *Postgrad Med J* 2000;76(896): 333-336.
2. Chen CM, Lin SH. Wall-Eyed Bilateral Internuclear Ophthalmoplegia From Lesions at Different Levels in the Brainstem. *Journal of Neuro-ophthalmology* 2007;27(1):9-15.
3. Chon J, Kim M. Bilateral internuclear ophthalmoplegia following head trauma. *Indian J Ophthalmol* 2017;65:246-7.
4. Ushio M, Iwasaki S, Chihara Y, Murofushi T. Wall-Eyed Bilateral Internuclear Ophthalmoplegia in a Patient with Progressive Supranuclear Palsy. *Journal of Neuro-ophthalmology* 2008;28(2):93-96.
5. Agarwal A, Vyas S, Banzal S, Jha RK. Wall-eyed bilateral internuclear ophthalmoplegia. *Neurology India* 2015; 63(3):444.
6. Garcia-Martin E, Pinilla I, Pueyo V, Gil L, Martinez-Morales J, Fernandez J. Bilateral Internuclear Ophthalmoplegia in a Patient with Devic's Neuromyelitis Optica. *Case Reports in Neurology* 2010;2(3):139-144.
7. Chakravarthi S, Keshav P, Khurana D. Wall-eyed bilateral internuclear ophthalmoplegia with vertical gaze palsy. *QJM: An International Journal of Medicine* 2013; 107(2): 165.
8. Kim JS, Jeong SH, Oh YM, Yang YS, Kim SY. Teaching NeuroImage: Wall-eyed bilateral internuclear ophthalmoplegia (WEBINO) from midbrain infarction. *Neurology* 2008; 70(8):e35.
9. Wu YT, Cafiero-Chin M, Marques C. Wall-eyed bilateral internuclear ophthalmoplegia: review of pathogenesis, diagnosis, prognosis and management. *Clin Exp Optom* 2015; 98(1):25-30.