

Postmortem Acute Death Obtained Brains without Reperfusion are Utilizable and Reliable to Examine the Expression of Hypoxia Related Antigens

Katsuji Nishi¹, Satoshi Furukawa¹, Satomu Morita¹, Masahito Hitosugi¹
Lisa Eberle²

¹ Department of Legal Medicine, Shiga University of Medical Science, Otsu, Shiga, Japan.

² Institute of Legal Medicine, Munich University, Munich, Germany.

Abstract

Background: It is widely accepted that the Purkinje cells in the cerebellum and the cells in the hippocampus are very vulnerable and sensitive to hypoxic circumstance. Many researchers believe firmly that the postmortem tissues are not suitable to investigate signal transduction in the cells, especially neurons.

Aim: However, we presumed that the vulnerability might be result from reperfusion occurred in the brain during agonal duration. Then, using by means of immunohistochemical method we examined the expression of hypoxia related antigens in the hippocampus, the cerebellum and the thalamus obtained from two individuals who acutely died due to self-strangulation without reperfusion of blood.

Methods and Results: We examined morphological changes and expression of hypoxic related antigens using conventional and immunohistochemical techniques. There was no remarkable damage such as pyknosis of the cell-nuclei, and vacuolation of the cell-cytoplasm by HE stain except weak edematous space around the cells at light microscopic level.

The antibodies against hypoxic related antigens showed reactivity with the cell cytoplasm or nuclei corresponding to their specificity. Although, anti Hypoxia inducible factor 1 alpha (HIF1 α) antibody known as the most famous one to detect hypoxic situation in the tissues showed very weak or feeble reactivity, antibodies against RNR binding protein motif 3 (RBM3), cold inducible RNA binding protein (CIRBP), endothelial nitric oxygenase synthase (eNOS), vascular endothelial growth factor (VEGF) and Heat shock protein 70 (HSP70) showed better reactivity than that by HIF1 α in those cells. The antibodies against apoptosis related antigens such as Apoptosis inducible factor (AIF), and tumor protein p53 (p53) showed feeble reactivity with these cells. The reactivity of anti eNOS antibody showed strange results among the brain regions.

Conclusions: The results obtained from present study may indicate that the brains obtained from acute death individuals keep its morphology and are in the signal pathway situation to protect hypoxic brain damages and not in a process from apoptotic to cell death.

The brain tissues without blood reperfusion might be utilize and reliable to evaluate and examine the cell functions at microscopic level.

Keywords: Hypoxic brain damages, Hypoxia related antigens, Acute hypoxic changes, Immunohistochemistry.

INTRODUCTION

It has been widely accepted that self-ligature strangulation was not able to make one's death, since lowering of consciousness occurred due to stopping of blood supply to the brain and subsequently the ligature was loosen when one would perform squeezing one's neck surface without apparatus for fixing the ligature. However, it is a fact that in forensic death investigation cases we have experienced and encountered self-strangulation death cases. We indicated in a previous report (1) that when one could keep the tension of a ligature at 5 Kg that is essential force to obstruct the cervical artery, after losing one's consciousness, two routes of blood stream to the brain may be stopped, and the tension with 2 Kg that is essential force to obstruct the internal jugular vein, could obstruct return-way to the heart and increase intracranial pressure. And we also described that the death mechanism including physiological- and anatomical-perspective view in a previous report (2).

As a confirmation of our assumption concerning with performing self-strangled death, Morita et al (3), reported a rare case in which a 71 year-old man was found dead on his bed, and it was

concluded by police investigation that he died due to stopping of returning of venous blood to the heart by compression of his neck-surface with a string drawn by a dumbbell with 3kg in weight. It is well known that the brain is particularly susceptible to interferences with its blood supply. In the absence of blood flow, and therefore of oxygen, the energy reserves of the brain are capable of sustaining ATP levels for about 1 min (4). We experienced one video recorded hanging case where a man attempt hanging and died within three minutes after his performance hanging (5).

In the adult human brain, acute hypoxic episodes result in a certain pattern of neuronal cell damage from which a hierarchy of neuronal vulnerability can be formed. Among the most sensitive regions are the "older" brain structures like hippocampus and cerebellum. In these structures, the typical picture is loss of pyramidal and Purkinje cells. Also, the neo-cortex is among the vulnerable structures, and often a characteristic laminar neuron loss is found. (6). Recently, it has been described that the Purkinje cells in the cerebellum and the cells in the hippocampus are very vulnerable and sensitive to hypoxic situation. However, the changes of these cells were observed in the cases where the death occurred after one day of event occurrence and re-perfusion of the brain was usually accompanied (7). In addition, these describing concerning to the neuronal damages were limited in cases where reperfusion in the brain occurred.

In our experience the level of pathological damaging of the granular cell layer of the cerebellum was severely in a hanging death with 24 hours reperfusion than those of a killed female by manual strangulation case in which her body was buried in a garden for 42 days (8). Since no study has examined the expression of hypoxia related antigens in the hippocampus and cerebellum of individuals who acutely and directly died due to self-strangulation, we examined the expression patterns of the hypoxic, apoptotic related antigens in the cerebellum and the hippocampus obtained from two victims who died due to self-strangulation using a T-shirt or a cotton rope (2).

MATERIALS AND METHODS

Slice of the hippocampus, thalamus and the cerebellum containing dentate nucleus from two victims at autopsy, Department of Legal Medicine, Shiga University of Medical Science. After fixed by 10% of formalin, paraffin embedded blocks were prepared and each block was cut with 3 μ m to mount on a slid-glasses. Non-specific binding was blocked for 1 h in suitable serum. The slides were incubated with different antibodies overnight at 4 C. The antibodies used in this study were listed in **Table 1**. Biotinylated antibodies and the avidin-biotin complex were applied for 90 min.

Table 1. Characteristics of the antibodies used in this study

Antibody	Maker	Clone	Species	Antigen-retrieval	incubation	Antibody-dilution
CIRBP	Protein Tech	10209-2-AP	Rabbit	autoclave	overnight	1:400
RBM3	Protein Tech	14363-1-AP	Rabbit	autoclave	overnight	1:400
HSP70	santa cruz	polyclonal	Goat	autoclave	overnight	1:400
HIF-1 α	Novus	NB100-479	Rabbit	autoclave	overnight	1:400
VEGF	Milipore	JH121	Mouse	autoclave	overnight	1:400
eNOS	Gene Tex	polyclonal	Rabbit	autoclave	overnight	pre-diluted
AIF- α	LSBio	aa-593-606	Rabbit	autoclave	overnight	1:400
P53	santa cruz	FL-393	Goat	autoclave	overnight	1:400
cFOS	Gene Tex	polyclonal:	Rabbit	autoclave	overnight	1:800
Ngb	SIGMA-ALDRICH	polyclonal	Rabbit	autoclave	overnight	1:400
Wnt	Novus	6F2	Mouse	autoclave	overnight	1:400
SIRT1	Novus	E104	Rabbit	autoclave	overnight	1:400
CCC9	Leica	10A6	Mouse	autoclave	overnight	1:400

Finally, diaminobenzidine (DAB) was added for 5 min for visualization. At each step, slide glasses were washed by phosphate buffered saline. Slides were dehydrated, dried, and covered with a cover glass.

RESULTS

1. HE staining

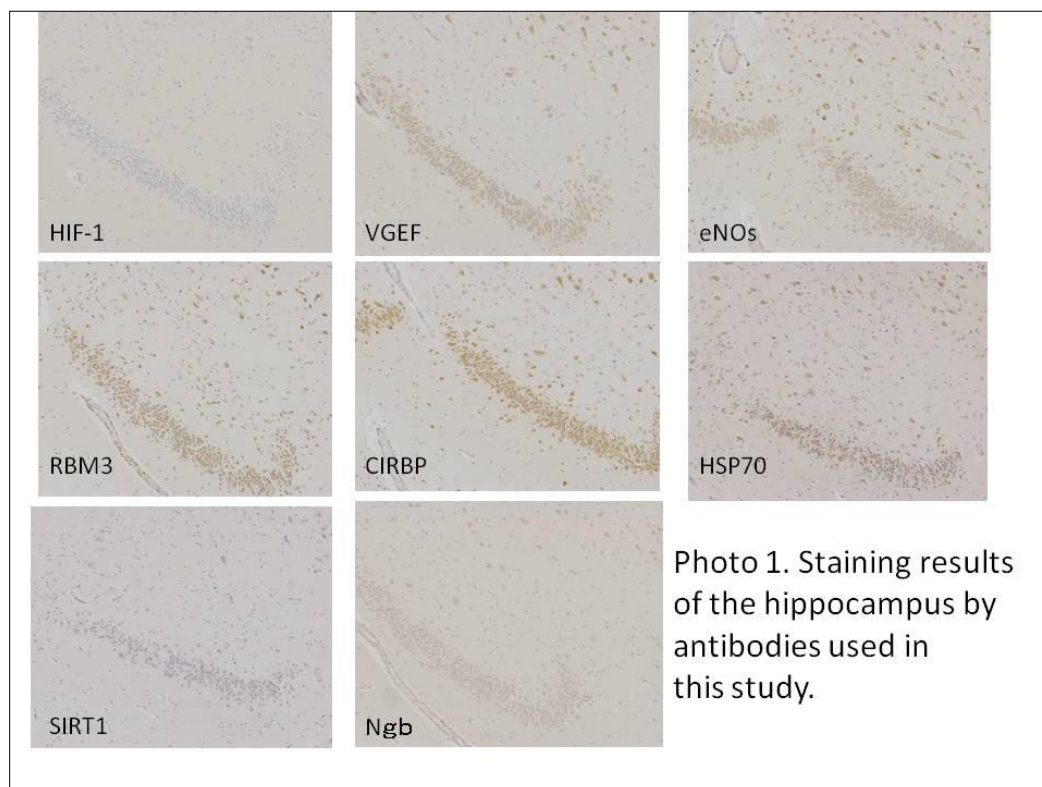
There was no remarkable decreasing of number of cells in granular cells and morphological changes of the cell nuclei in the cerebellum and hippocampus dentate gyrus. The same morphological situation was observed in other region of hippocampus containing C1 to C4 regions, the cerebellum containing the Purkinje cells and dentate nucleus and the neurons in the thalamus from two individuals.

2. Immunohistochemical staining

2-1 The hippocampus

Antibodies against RBM3, CIRBP, e-NOS, HSP70, VEGF and Neuro globulin (Ngb) could stain the cells in granular cells of dentate gyrus, and the cells in C1 to C4 regions showing different stainability by each antibody. For example, anti RBM3 and CIRBP stained nuclei with clear and intensive reactivity, and other antibodies such as VEGF, HSP70 and e-NOS stained cytoplasm of the cells with moderate reactivity. Anti Ngb showed weak reactivity with cytoplasm. On the other hands, antibodies against HIF1, SIRT1, p53, AIF α , and CCC9 showed no reactivity in these cells. The staining results of the granular cell layer are shown in the

Photo 1.



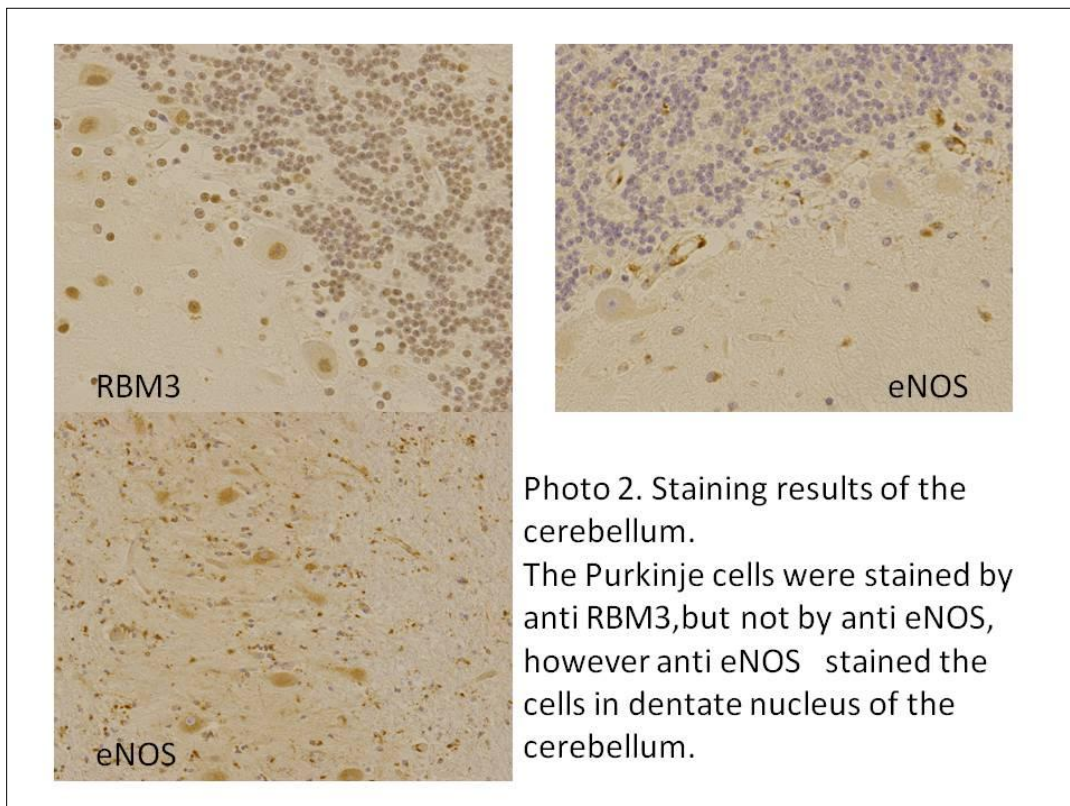
2-2 The thalamus

Antibodies against RBM3, CIRBP and eNOS showed clear and good reactivity with the nuclei or cytoplasm of neurons in the thalamus. Antibodies against HSP70, and VEGF showed weak or moderate reactivity with the neurons. Antibodies against SIRT, HIF1 α , p53, AIF and CCC9 showed feeble reactivity with neurons in the thalamus.

2-3 The cerebellum

Antibodies against CIRBP and RBM3 showed clear reactivity with the cells in the granular cell layer and anti HSP70 antibody showed weak reactivity with these cells. However antibodies against HIF1 α , SIRT 1, Ngb, cFOS and P53 showed no reactivity with these cells.

The Purkinje cells showed intensive reactivity with CIRBP and RBM3 in the nuclei and weak reactivity with Ngb, c-FOS, CC9 and P53 in cytoplasm of them. No reactivity was observed with antibodies against HSP70, HIF1 α , SIRT1 and eNOS in the Purkinje cells. There was one different in the stain-ability of the Purkinje cells between anti RBM3 and CIRBP antibodies. Anti RBM3 reacted only with nuclei and anti CIRBP reacted both with nuclei and cytoplasm of the Purkinje cells. The cells in the molecular layer showed intensive with anti CIRBP and RBM3 antibodies, moderate with antibodies against CC9, SIRT1, HIF1 α and HSP70. Anti HSP70 showed clear reactivity with the cells in the Purkinje cell line.



Regarding to the cells in the dentate nucleus all antibodies except anti SIRT1, AIF1 and VEGF antibodies showed reactivity in a variety of stain-ability. Although anti eNOS showed no reactivity with Purkinje cells and cells of molecular layer, this antibody showed clear reactivity in the cells of the dentate nucleus as shown in **Photo 2** with extension of the reaction time at each step.

3. Choroid plexus

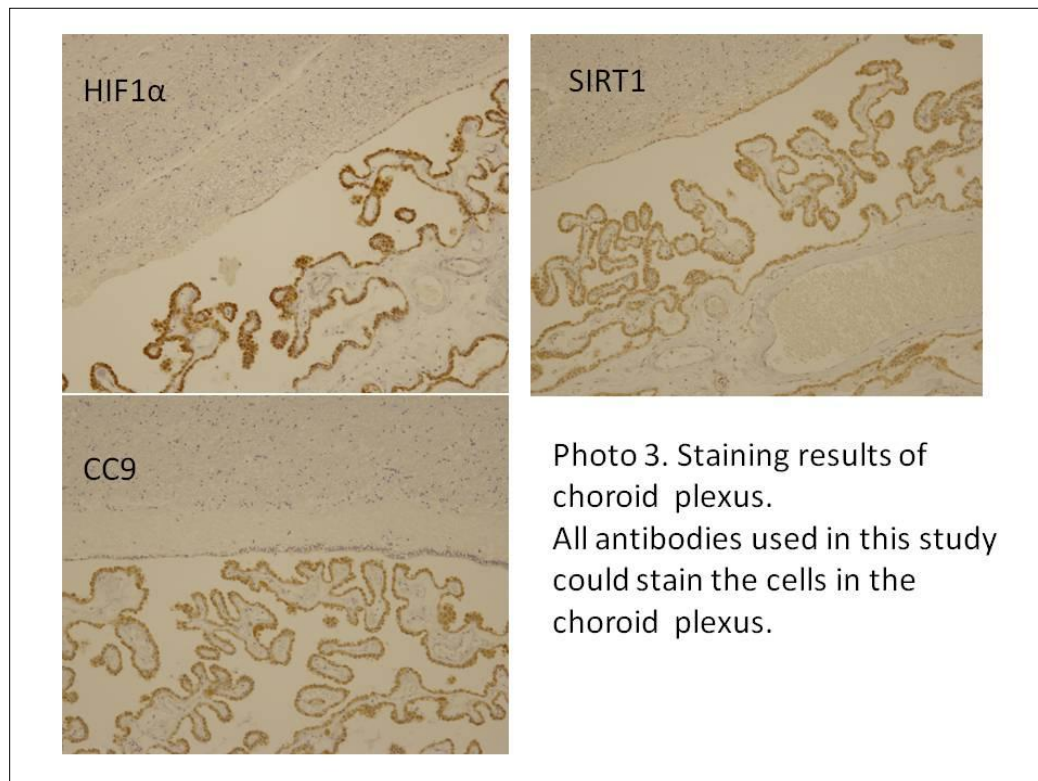
In the choroid plexus the staining results were dissociated by those obtained from other regions. Although the staining intensity was different among the antibodies, all antibodies showed good reactivity with the cell in the choroid plexus. Staining results were shown in **Photo 3**.

4. Summary of staining results

Each region collected from brains of individuals who died due to self-strangulation has kept stain-ability by antibodies against hypoxic related antigens although the staining intensity was different among the antibodies. The stainability of each antibody was similar between two individuals.

DISCUSSION

The present and previous observations (8) with HE stain indicate that brain tissues obtained from acute deaths without reperfusion of blood stream are reliable and useful to examine histochemical characteristics of human post-mortem brain.



The brain is the organ that is most susceptible to a variety of hypoxic insults such as are brought about by cardiac arrest, status epilepticus and hypoglycemia in clinical medicine (9). In addition to them, there are many insults such as drowning, chest- and neck-compression and anaphylaxis shock in forensic field.

We previously studied the expression of hypoxic related antigens such as HIF1 α , SIRT1, RBM3, CIRBP, e-NOS, HSP70, VEGF and NgB in the thalamus obtained from two case of self-ligature strangulation death (2).

Malhotra et al (10) and Carmeliet et al (11) reported that HIF1 played a master regulatory role in the cellular response to hypoxia. In certain circumstances and in certain cell types, HIF1 promoted apoptosis in the presence of hypoxia, especially when other cellular energy substrates were lacking. It is now well accepted that hypoxic-ischemic brain damage following asphyxia and/or blood flow disruption occurs in a biphasic manner, which are necrosis and apoptosis (12). Since the decubitus ulcer does not occur during postmortem interval, the decubitus ulcer occurs in reperfusion of blood supply after sever compression of the skin, during reperfusion with progressing of the cascade of signal pathway, apoptosis or necrosis of the skin become to be reliable and be remarkable.

Dalkara et al (13) reported that enhanced NO production within the cerebral vasculature protects brain tissue during focal ischemia via hemodynamic mechanisms whereas neuronal

overproduction may facilitate or mediate neurotoxicity. Samdani et al (14) described that eNOS plays a prominent role in maintaining cerebral blood flow and preventing neuronal injury. Bolanos JP and Almerida A (15) reported that activation of nNOS or induction of iNOS mediates ischemic brain damage, possibly by mitochondrial dysfunction and energy depletion. However, eNOS activation within the endothelium of blood vessels mediates vasodilatation and hence increases blood flow to the damaged brain area. Although few works show e-NOs location in the cerebellum, studies by Hernandez et al (16) and Shin et al (17) have found e-NOs in Purkinje cells and neurons of the cerebellum nucleus. Iwase et al (18) suggested that brain eNOS is involved in early pathophysiological response against systemic infection before iNOS is induced with progression of the infection. In the present study anti eNOS antibody showed intensive reactivity with the cytoplasm of cells in the dentate nucleus of the cerebellum, however feeble reactivity was detected in the Purkinje cells. This phenomenon is not consistent with the reports described above. The expression of eNOS might not detected due to delay of signal cascade in cells, since the expression of eNOS was related with the expression of HIF1 α (19) and the feeble expression of HIF1 α was observed in this study. It is well accepted that HIF1 which closely relate with the prevention of hypoxic control and manages to expression of VEGF, and the expression of VEGF is

connected with the expression of e-NOS, since Qing et al (19) have proposed that the response to hypoxia is primarily mediated by the transcription factor hypoxia-inducible factor-1 (HIF-1) which leads to the induction of a variety of adaptive gene products including VEGF and eNOS.

In our examinations indicated that expression manner between RBM3 and HIF1 α was different in the substantia nigra (20, 21) obtained from same individuals and expression of RBM3 was more intensive compared with that of eNOS (22), showing expression of RBM3 was independent of cascade in HIF1 α pathway.

Although the signaling cascades upstream and downstream of RBM3 and CIRBP remain to be elucidated, the up-regulation of RBM3 and CIRBP in the case of hypothermic (23) and hypoxic/ischemic deaths may rescue neuronal cells from apoptosis. Smart et al (24) reported that RBM was expressed in multiple brain regions, with the highest levels in cerebellum and in dissociated neurons RBM3 was observed in nuclei and in a heterogenous population of granules within dendrites, and RBM3 plays a distinctive role in enhancing translation in neurons. In our experiences no expression of RBM3 was observed in the nuclei inside the acute infarcted area of the myocardium (25) and nuclei in the substantia nigra cells from the victims with cirrhosis or brain crush (22). Regarding to expression of RBM3 and eNOS, we experienced that although both antigens could be detected in ischemic area of the cardiac

tissue where located surrounding of cardiac infarction area, weak reactivity with anti eNOS antibody was observed and no reactivity with anti RBM3 was recognized inside the infarction area (25). This experience indicate that expression of both antigens are also independent each other.

The future study will be undertaken with the aim of answering the question; is the expression pattern of antigens examined in this study in C1 to C4 areas, dentate gyrus of the hippocampus and in the cerebellum similar or different compared with those of the basal ganglia and the hypothalamus?

SUMMARY

The degree of damages occurred in the brain cells due to ischemic is based on the period of agonal duration and re-perfusion. The brain tissues obtained from acute and direct death individuals may be appropriate to examine the cascade and/or signal pathway in the cells, since many antigens, such as eNOS, RBM3, ICRBP, VGEF, and HSP, were expressed in the hypoxic situation even in the hippocampus and/or the Purkinje cells known as the most vulnerable regions in the brain, and no or feeble expression of apoptotic and inflammatory antigens were observed in those regions.

Acknowledgments: author's work was partially supported by a Japanese Grant in Aid Scientific Research C (2640876) for K Nishi.

Conflict of interest disclosure: Not available.

REFERENCES

- 1 Yamasaki S, Takase I, Takata N, Nishi K. Measurement of force to obstruct the cervical arteries and distribution of tension exerted on a ligature in hanging *Legal Med* 2009;11,175-180.
- 2 Furukawa S, Sakaguchi I, Morita S, Nakagawa T, Takaya A, Wingefeld L, Nishi K. Suicidal ligature strangulation without an auxiliary mechanism. Reports of two cases with a cotton rope or a T-shirt and staining results of the brains using anti HSP-70, CIRBP, RBM3, HIF1 α , SIRT1 and p53 antibodies *Rom J Leg Med* 2313: 21, 9-14.
- 3 Morita S, Furukawa S, Nishi K, Hitosugi M, Matsumoto H. A death due to neck compression by a string towed iron dumbbell with 3 kg, 61st annual meeting of Kyushu district, Japanese Association of Legal Medicine, 2014, In Japanese.
- 4 Lust WD, Yasumoto Y, Wittingham TS, Djuricic B, Mrsulja BB, Passonneau J, Ischemic encephalopathy, in: McCandless D.W. (Ed.), *Cerebral Energy Metabolism and Metabolic Encephalopathy*, Plenum Press, New York, 1985, pp. 79–112.
- 5 Yamasaki S, Kobayashi AK, and Nishi K. Evaluation of suicide by hanging: From the video recording *Forensic Sci Med Pathol* 2007;3:45-51.
- 6 Cervos-Navarro J, Diemer NH. Selective vulnerability in brain hypoxia *Critical Reviews in Neurobiology*1991;6,149-182.
- 7 Dirnagl U, Iadecola C, Moskowitz MA. Pathobiology of ischemic stroke: an integrated view *Trends Neurosci* 1999;22:391-397.
- 8 Morita S, Furukawa S, Takaya A, Sakaguchi I, Okunaga H, Nakagawa T, Wingefeld L, Nishi K. Usability of histological assessment of cerebellar granule cell layer regardless of postmortem interval *J Forensic Res* 2013; 4:180.
- 9 Ng T, Graham DI, Adams JH, Ford I. Changes in the hippocampus and the cerebellum resulting from hypoxic insults: frequency and distribution *Acta Neuropathol*1989;78:438-443.
- 10 Malhotra R, Tyson DW, Rosevear HM, Brosius III F. Hypoxia-inducible factor 1 alpha is a critical mediator of hypoxia induced apoptosis in cardiac H9c2 and kidney epithelial HK-2 cells. *BMC cardiovascular Disorders* 2008;8:9,
- 11 Carmeliet P, Dor Y, Herbert J-M, Fukumara D, Brusselmans K, Dewerchin M, et al. Role of HIF-1 α in hypoxia-mediated apoptosis, cell proliferation and tumor angiogenesis *Nature*1998;394:485–90.
- 12 Northington FJ, Ferriero DM, Graham EM, Traystman RJ, Martin LJ, Early neurodegeneration after hypoxia-ischemia in neonatal rat is necrosis while delayed neuronal death is apoptosis *NeurobiolDis* 2001; 8, 207-19.
- 13 Dalkara T, Yoshida T, Irikura K, Moskowitz M A. Dual role of nitric oxide in focal cerebral ischemia *Neuropharmacology* 1994;33:1447-52.
- 14 Samdani AF, Dawson TM, Dawson VL. Nitric oxide synthase in models of focal ischemia *Stroke* 1997;28:1283-88.
- 15 Bolanos JP, Almerida A, Roles of nitric oxide in brain hypoxia-ischemia *BBA Bioenergetics* 1999;1411:415-36.
- 16 Hernandez R, Martinez-Lara E, Del Moral ML, Blanco S, Canuelo A, Siles E, et al. Up-regulation of endothelial nitric oxide synthase maintains nitric oxide production in the cerebellum of thioacetamide cirrhotic rats *Neuroscience* 2004;126:879-87.
- 17 Shin T, Weinstock D, Castro MD, Hamir AN, Wampler T, Walter M, et al. Immunohistochemical localization of endothelial and inducible nitric oxide synthase within neurons of cattle rabies. *J Vet Med Sci* 2004;66:539-41.
- 18 Iwase K, Miyanaka K, Shimizu A, Nagasaki A, Gotho T, Mori M, Takiguchi M. Induction of endothelial nitric-oxide synthase in rat brain astrocytes by systemic lipopolysaccharide treatment *JBC*2000; 275:11929-33.
- 19 Qing M, Goerlach M, Schumacher K, Woeltje M, Vazquez-Jimenez JF, Hess J, Seghaye MC. The hypoxia-inducible factor HIF-1 promotes intramyocardial expression of VEGF in infants with congenital cardiac defects *Basic Res Cardiol* 2007;102: 224-32.

- 20 Furukawa S, Morita S, Hitosugi M, Wingenfeld L, Nishi K. Histochemical difference of Neurons in Substantia Nigra induced by Global ischemia/hypoxia. *AJMHS* 2015;46:13-20.
- 21 Nishi K, Furukawa S, Morita S, Hitosugi M, Erbele L. Expression of RNA binding motif protein 3 (RBM3) in the Substantia Nigra might be utilize to distingue neck compression deaths from other deaths *Review of Albanian Legal Med* 2016 in Press.
- 22 Furukawa S, Morita S, Wingenfeld L, Hitosugi M, Nishi K. RBM3 and CIRP may play an important role as a vasodilator. A preliminary study *Review of Albanian Legal Med* 2015:11:74-84.
- 23 Morita S, Furukawa S, Wingenfeld L, Matsuda W, Nishi K. Difference in the expression of CIRBP, RBM3 and HSP70 in the myocardium and cerebellum after death by hypothermia and carbon monoxide poisoning *Rom J Leg Med* 2013:21:219-24.
- 24 Smart F1, Aschrafi A, Atkins A, Owens GC, Pilotte J, Cunningham BA, Vanderklisch PW. Two isoforms of the cold-inducible mRNA-binding protein RBM3 localize to dendrites and promote translation *J Neurochem* 2007; 101:1367-79.
- 25 Furukawa S, Kataoka M, Morita S, Uno A, Hitosugi M, Matsumoto H, Nishi K. Histochemical characteristics of myocardium obtained from two huge cardiomegaly with over 1000g in weight *SM J Clin Med* 2016;2: 1011-15.